

# LC MS/MS Phytochemical analysis of *Ruta montana* and the Hepatic Preventive Effects in male Rats exposed to Tebuconazole

Badis Aouzal<sup>1</sup>, Souheila Slimani<sup>1</sup>, Fatima Kamah<sup>1</sup>, Ismahane Ounissi<sup>1</sup>, Anissa Bouacha<sup>1</sup> and Samira Elmokli<sup>2</sup>

<sup>1</sup>Research Laboratory of Interactions, Biodiversity, Ecosystems and Biotechnology, Department of Nature and Life Sciences, Faculty of Sciences, University 20 August 1955 Skikda, Skikda 21000, Algeria

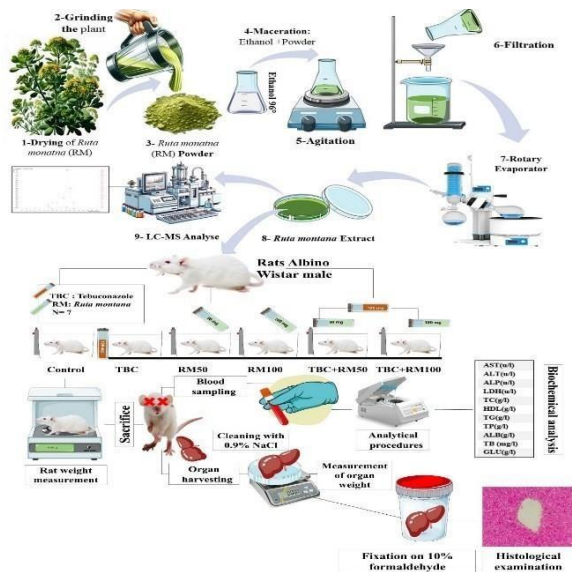
<sup>2</sup>Laboratory of anatomopathology Saad Guermech hospital Skikda 21000, Algeria

Received: 08/10/2024, Accepted: 30/10/2024, Available online: 05/11/2024

\*to whom all correspondence should be addressed: e-mail: badisaouzal@gmail.com

<https://doi.org/10.30955/gnj.06877>

## Graphical abstract



## Abstract

In this investigation, we assessed the phytochemical composition and hepatoprotective properties of *Ruta montana*, a plant indigenous to Algeria, against liver damage provoked by the systemic fungicide tebuconazole in male Wistar rats. We distributed forty-two rats, each weighing an average of  $178 \pm 67.2$  g, into six groups consisting of seven animals each. The first group, serving as the control, received no intervention. The second group underwent treatment with tebuconazole at a concentration of 100 mg/kg. The third and fourth groups were treated with *Ruta montana* extracts at dosages of 50 mg/kg and 100 mg/kg, respectively. The fifth and sixth groups received combined treatments of tebuconazole (100 mg/kg) and *Ruta montana* extracts at 50 mg/kg and 100 mg/kg, respectively. Over a period of 50 days, we administered these treatments via oral gavage. The ethanolic extract of *Ruta montana*, prepared through maceration, underwent analysis using LC-MS/MS, which revealed the presence of nine significant phenolic compounds. The findings demonstrate that exposure to

tebuconazole significantly decreased both body and liver weights, and notably altered levels of hepatic enzymes (AST, ALT), indicative of liver toxicity. In contrast, treatment with *Ruta montana* extract ameliorated these adverse effects, confirming its protective efficacy. Histopathological examinations further substantiated the amelioration of liver tissue damage in rats receiving the plant extract. This research underscores the significant role of bioactive phenolic compounds in *Ruta montana* in mitigating hepatic injuries induced by tebuconazole, thereby highlighting its potential therapeutic benefits.

**Keywords:** *Ruta montana*, LC-MS, Tebuconazole, Rat, Liver.

## 1. Introduction

The liver, being the primary organ responsible for metabolizing foreign substances, is vulnerable to damage that can lead to many disorders including hepatitis, cirrhosis, and hepatocellular cancer. Exposure to various environmental contaminants and chemicals is a significant contributing factor to the development of many illnesses. (Alter, 2006).

Conazole, such as tebuconazole fungicides (TBC), are compounds that belong to the triazole family (Bošković *et al.* 2021). Tebuconazole plays a crucial role in modern agriculture, it's used to manage a diverse range of fungal infections, such as grains, crops, and fruit and vegetables (Li *et al.* 2012; Ben Othmène *et al.* 2020). However, its widespread application has led to potential exposure among mammals (De Rossi *et al.* 2003). Substantial evidence from multiple studies Ben Othmène *et al.* (2020) suggests that exposure to tebuconazole, absorbed through various pathways, may elicit health implications and induce pathological changes across several organs (Goetz *et al.* 2007).

The TBC exposure can cause immunological, neurobehavioral, and neuropathological insufficiency (Ben Saad *et al.* 2017). Some toxicological investigations have revealed that tebuconazole can also lead to elevated chromosomal Occurrences of abnormalities and exchanges between sister chromatids in lymphocytes from the

peripheral blood of cows (Yang *et al.* 2019). The administration of tebuconazole manifested in increased mRNA levels of Cyp1a2, Cyp2b10, Cyp3a11, and NADPH-cytochrome P450 reductase in the hepatocytes of mice (Tamura *et al.* 2013). So, TBC stands as a formidable xenobiotic that, upon exposure, could potentially induce liver toxicity and oxidative stress (Joshi *et al.* 2016), metabolic alterations (Ku *et al.* 2021) and even mortality across diverse organisms (Perez-Rodriguez *et al.* 2019; Bernabò *et al.* 2016).

Furthermore, plants containing medicinal properties have been utilized traditionally as a form of natural treatment for a wide variety of diseases and ailments (Dolatkhahi *et al.* 2014) to prevent different intoxication (De-Giffoni de-Carvalho *et al.* 2019) and safeguard against the effects of oxidative stress and the damage caused by free radicals (Asao et Asaduzzaman, 2018). *Ruta montana*, also known as wild rue or mountain rue, belongs to the Rutaceae family and it is an herbaceous plant with alternate, fetid, simple, stipulate leaves, and hermaphrodite flowers (Bouhenna *et al.* 2023).

*R. montana*, contains bioactive compounds, such as coumarins and phenols, alkaloids, flavones, and tannins, which are bioactive compounds that contribute to its medicinal properties (kara *et al.* 2016; Mahdeb *et al.* 2023; Bouhenna *et al.* 2023). Some of these compounds may have anti-inflammatory properties (Zeichen *et al.* 2000; Raghav *et al.* 2006). The plant also contains compounds that have been found to have anticancer activity in animal studies (Adamska-Szewczyk *et al.* 2016; Farid *et al.* 2017), as well as antioxidant properties (Djeridane *et al.* 2006; Farid *et al.* 2017) it is also traditionally used in the treatment of various skin pathologies (Mohammedi *et al.* 2020). recent study's like Mahdeb *et al.* 2023 demonstrate that the extract had a substantial antibacterial, antifungal, antidiabetic, and insecticidal property. Others like El-Ouady et Eddouks. (2021) elucidate the beneficial impact of *Ruta montana* in hypertension management, consequently advocating for its utilization as an antihypertensive therapy (El-Ouady et Eddouks, 2021). While some have suggested in the realm of therapeutic applications, the *R. montana*, poultice has garnered commendation for its efficacy in mitigating the deleterious effects of envenomation from snakes and scorpions, while its powdered form is lauded for its capacity to ameliorate symptoms of facial paralysis (Benkhaira *et al.* 2022).

*Ruta montana*, a plant esteemed within the realms of traditional medicine for its therapeutic attributes, presently encounters a deficit in rigorous scientific corroboration concerning its medicinal efficacy and capability for detoxification. Preliminary investigations have identified constituents within *Ruta montana* that may exhibit hepatoprotective qualities. However, a detailed exploration is imperative to ascertain the full spectrum of its therapeutic advantages and the associated risk profile in relation to liver health. This inquiry delves into the phytochemical composition of *Ruta montana*, assessing its potential role in counteracting the adverse effects resulting from tebuconazole exposure in male Wistar rats, with a

focus on evaluating whether its intrinsic molecular properties found in *R. montana* confer protective benefits to hepatic functions.

## 2. Materials and methods

### 2.1. Chemicals

Tebuconazole ( $C_{16}H_{22}ClN_3O$ ), a triazole fungicide commercialized as Medalion®, contained 430 g/L of Tebuconazole is used in this investigation. It was manufactured by Rotam Agrochemical (HK) Co.

#### 2.1.1. Plant

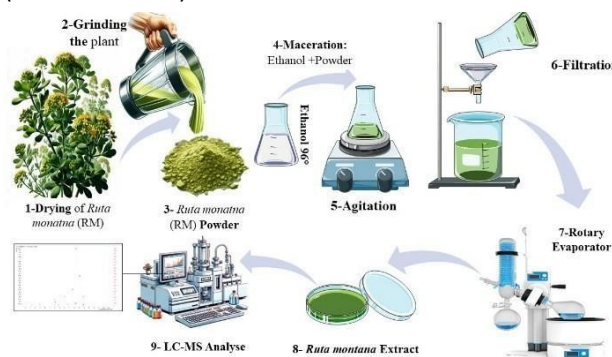*Ruta montana* was collected from Tassadane Haddada, located in the extreme northwest of the province of Mila, Algeria. It was identified, dried, meticulously cleaned, ground, and filtered to obtain a fine powder (Figure 1).

#### 2.1.2. Ethanolic compounds extraction

The ethanolic extract was obtained by maceration of *Ruta montana* in ethanol at 96° for 72 h. Wattman® paper was used to filter the extraction that's been generated. The obtained solvent is placed in the Rotation and evaporation device (DLAB R E 100-Pro Rotary Evaporator) (Figure 1).

### 2.2. LC-MS

LC-MS analysis was used to investigate the phenolic constituents in Ethanolic extracts of the aerial parts of *R. montana*. This analysis was carried out by LC-MS/MS (Agilent Technologies 1260 Infinity II, 6460 Triple Quad Mass spectrometer). The analytical methodology involved the utilization of a Poroshell 120 SB-C18 chromatographic column featuring dimensions of 3.0 × 100 millimeters in inner diameter and possessing a particle size of 2.7 micrometers (Erenler *et al.* 2019). Data acquisition was conducted and processed utilizing Mass Hunter software (version B.07.01).



**Figure 1.** Illustration of the sequential phases of the phytochemical study by Lc-MS, encompassing the extraction process.

#### 2.2.1. Animals

This investigation received formal approval from the Ethical Committee of the Directorate General for Scientific Research and Technological Development, operating under the auspices of the Ministry of Higher Education and Scientific Research.

Forty two Albino wistar males' rats with an average weight of  $178 \pm 67.2$  were supplied by the Pasteur Institute, Algiers- Algeria. Rats were accommodated in Animal house at ambient temperature of  $23 \pm 2^\circ C$ , 40 of humidity and

natural photoperiod. They were fed on standard laboratory diet and water *ad libitum*.

### 2.2.2. Experimental Design

The rats were divided into six groups, of seven animals in each: Control group (C), group (TBC) orally gaved with 100 mg/kg/day of Tebuconazole. RM50 group received 50 mg/kg bw of Ruta extract, and RM100 group received 100 mg/kg bw of Ruta extract. The fifth and the sixth groups were administered by a combination of TBC+RM50 and TBC+RM100, respectively.

The TBC dose was chosen on the basis of previous study of Berrouague *et al.* (2019), with 1/17 of LD50 (Ben-Saad *et al.* 2017). However, the extract was solubilized in distilled water to formulate two doses selected according to Allouni *et al.* (2017) with LD50 of 389,04 mg/kg fond in mice.

During the experiment, the body weight was recorded every 5 days regularly. At 50 day the animals were fasted overnight. They were sacrificed by cervical decapitation without anesthesia to reduce animal's stress.

### 2.2.3. Biochemical analysis

Blood samples were meticulously extracted blood from the cardiac cavities, subsequently transferring them into tubes laced with heparin, followed by a centrifugation process at 3000 revolutions per minute for a span of 20 minutes under a temperature controlled at 4 degrees Celsius. The isolated plasma served as the basis for conducting a comprehensive biochemical analysis, focusing on the quantification of alanine aminotransferase, glutamyl transferase, alkaline phosphatase, total bilirubin, proteins, and albumin, utilizing an array of diagnostic kits sourced from Randox Laboratories, Ardmore, Northern Ireland, UK, analyzed through the precision of a MINDRAY® BS 2000 analyzer. Additionally, the evaluation of plasma glucose levels was performed with kits obtained from Diamond Diagnostics, while the measurement of total cholesterol, high-density lipoprotein, and triglycerides was executed through colorimetric techniques facilitated by Randox's chemical reagents.

Following the euthanasia of the subjects, their livers were promptly excised, cleansed with a saline solution at a concentration of 0.9% sodium chloride, and then weighed; the relative liver weight was determined as grams per 100 grams of body mass. For histological examination, liver samples underwent fixation in a 10% formaldehyde solution for 24 hours, followed by progressive dehydration through a series of graded alcohol solutions. Subsequent to their clarification in toluene, the specimens were encapsulated in paraffin wax. For microscopic analysis, sections with a thickness of 5 micrometers were prepared, affixed to slides treated with diethyl phthalate xylene, and stained with hematoxylin and eosin (Martoja, 1967).

### 2.2.4. Statistical analysis

Statistical results are articulated as the mean  $\pm$  standard error of the mean (SEM). The analytical process encompassed a one-way analysis of variance (ANOVA) for the initial determination of significance, succeeded by post-hoc multiple comparisons utilizing Tukey's test, with a significance threshold set at  $p \leq 0.05$ . This analysis was

conducted employing the software packages Microsoft Excel 2021® (Version 2401, Microsoft Corp., Redmond, WA, USA) and GraphPad Prism version 9® (GraphPad Software, LLC, CA, USA).

## 3. Results

### 3.1. LC-MS Analysis

The tested extract was analyzed using an LC-ESI-MS instrument. The obtained chromatograms were processed by the Qualitative Analysis B.07.01 software from Agilent Mass Hunter Work-Station technologies. Our investigation of different bioactive compounds in the *Ruta montana* led to the identification of 9 compounds: Protocatechuic acid, Hydroxybenzaldehyde, acid, Salicylic Acid, Hesperidin, Kaempferol-3-glucoside and Luteolin. The identified compounds are represented in **Table 1**.

Mean  $\pm$  SEM of Body and liver weights of control and rats treated with *Ruta montana* (RM), Tebuconazole (TBC), and combined treatments of Tebuconazole with *Ruta montana* after 50 days. All data are expressed as Means  $\pm$  SEM (n=7); values are significantly different ( $*p < 0.05$ ) compared with the control group.

#### 3.1.1. Effects of treatment on general rats' health

Throughout the duration of the study, no instances of morbidity or mortality were observed in rats subjected to treatments with Tebuconazole (TBC), *Ruta montana* (RM), or a combination of both. However, within the group receiving TBC, there were noted occurrences of diarrhea, a reduction in food consumption, and disequilibrium, indicative of adverse effects associated with this specific treatment across the experimental timeline.

#### 3.1.2. Effects of treatment on body and liver weights:

As shown in **Table 2**, the body weight was significantly ( $P \leq 0.05$ ) decreased in TBC group and insignificant decrease in all other treated groups. The absolute and the relative liver weights were decreased in all treated, it was statistically significant ( $P \leq 0.01$ ) in TBC+RM50 group

#### 3.2. Effect of treatment on plasma biochemical Parameters

Our data mentioned in **Figure 2** indicated that TBC can induce liver toxicity. Results revealed a significant increase ( $p \leq 0.001$ ) in hepatic enzyme activities (ALT, AST, LDH and ALP). In addition, rats treated with 100 mg of TBC showed a significant increase ( $p \leq 0.001$ ) in total cholesterol, HDL, triglycerides, and total bilirubin blood levels. While, a significant reduce ( $P \leq 0.001$ ) in plasma albumin compared to controls. Supplementation of *Ruta montana* extract restored all biochemical parameters studied.

#### 3.3. Histopathological results

The histological examination of the liver sections is shown in **Figure 3** respectively. The control section showed a normal hepatic parenchyma. However, liver section of TBC treated rats showed a various pathological deterioration, mainly represented by vascular congestion, sinus dilation, periportal inflammatory infiltrate or portal necrosis, and hepatitis.

**Table 1.** Phenolic compound composition identified using LC-MS analysis.

No	Name	<i>Ruta montana</i> (mg/g in plant extract)	Ion Source	RT	Ion Transitions	Ion Mod	R2	LOQ(ug/L)	LOD(ug/L)	Linearity Range(ug/L)
1	Protocatechuic acid	0,0251568	ESI	5,449	153.0 -> 109.0	Positive	0,9969	13,1729	3,1564	15.625-250
2	Hydroxybenzaldehyde	0,0324748	ESI	7,679	121.0 -> 92.0	Positive	0,9993	12,8651	4,9742	15.625-250
3	Vanillin	0,0444	ESI	8,649	153.0 -> 125.0	Positive	0,9949	40,5411	14,5885	62,5-1000
4	p-coumaric acid	0,0519758	ESI	9,441	163.0 -> 119.1	Positive	0,9996	7,9973	4,0164	15.625-500
5	Salicylic acid	0,2049716	ESI	9,539	137.0 -> 93.1	Positive	0,9981	82,9646	47,6695	112.5-1800
6	Hesperidin	22,8657336	ESI	11,842	611.0 -> 302.9	Positive	0,9957	17,6753	4,1396	31.25-500
7	Isoquercitrin	0,5499434	ESI	11,867	464.9 -> 302.8	Positive	0,9982	11,2680	9,9382	18.75-300
8	Kaempferol-3-glucoside	0,0109754	ESI	13,287	448.8 -> 286.9	Positive	0,9997	4,5238	1,1609	7.8125-125
9	Luteolin	0,3431152	ESI	17,909	285.0 -> 133.1	Positive	0,9962	21,4535	20,0000	31.25-500

**Table 2.** Effects of treatment on body and liver weights.

Mean $\pm$ SEM	Treatment groups					
	Control	TBC100	RM50	RM100	TBC+RM50	TBC+RM100
	mg/kg/bw/d					
Initial body Wight (g)	241,4 $\pm$ 10,39	242,6 $\pm$ 11,19	232,7 $\pm$ 8,585	232,3 $\pm$ 7,921	231,4 $\pm$ 8,08	237,6 $\pm$ 7,077
Final body Wight (g)	254,4 $\pm$ 11,42	204,3 $\pm$ 16,24*	215,6 $\pm$ 7,671	213,9 $\pm$ 12,98	210,9 $\pm$ 10,36	227,4 $\pm$ 11,86
Absolute Weights of the liver (g)	9,457 $\pm$ 0,6	8,057 $\pm$ 0,20	8,571 $\pm$ 0,26	8,314 $\pm$ 0,28	7,1 $\pm$ 0,38**	8,886 $\pm$ 0,46
Relative Wight of the liver (g)	3,711 $\pm$ 0,17	3,248 $\pm$ 0,48	3,66 $\pm$ 0,15	3,969 $\pm$ 0,26	3,406 $\pm$ 0,21	3,986 $\pm$ 0,31

Mean  $\pm$  SEM of Body and liver weights of control and rats treated with *Ruta montana* (RM), Tebuconazole (TBC), and combined treatments of Tebuconazole with *Ruta montana* after 50 days. All data are expressed as Means $\pm$  SEM (n=7); values are significantly different (\*p<0.05), (\*\*p<0.01) compared with the control group.

#### 4. Discussion

Liver dysfunction emerges as a paramount concern in the metabolic processing of pharmaceuticals and xenobiotics, underscored by extensive research (Cepa *et al.* 2018). Further analysis of scientific literature indicates that the toxicological impact of pesticides and various chemicals is predominantly mediated through the induction of oxidative stress by free radicals (Abdollahi *et al.* 2004). So, it is becoming urgent to explore, identify, and develop alternative therapeutic approaches to help against the harmful effects of xenobiotics on liver function. Among various communities, especially in Africa, the use of herbal remedies as an alternative or adjunct therapeutic intervention for a wide array of ailments is prevalent and culturally ingrained (Akinrinde *et al.* 2018; Bouzana *et al.* 2023). Due to their antioxidant properties against radicals mainly produced by xenobiotics, herbs are actually employed for their therapeutic and preventive advantages against liver illnesses (Hussein *et al.* 2016).

In our experiment involving the extraction of *Ruta montana*, a yield of 11.994% was achieved through ethanol maceration of the plant's dry powder. This result closely

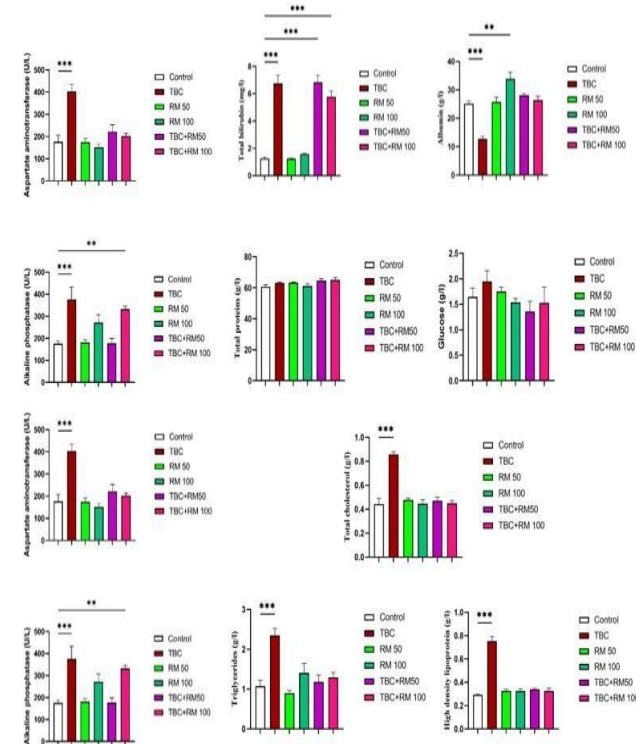
aligns with Ghedjati *et al.*'s findings of a 12.42% yield in 2022, surpassing the yield reported by Mahdeb *et al.* (2023). Numerous factors influence this variation, including the duration of maceration, the plant's chemical profile, which can fluctuate based on geographical location and harvest timing, the developmental stage of the harvested plant parts, soil characteristics, climatic conditions (Brown *et al.* 2012; Özcan et Chaichat. 2005), and the choice of extraction solvent (Kalt *et al.* 2001).

The phytochemical analysis of *Ruta montana* using LC-MS/MS led to the identification of nine key compounds: protocatechuic acid, hydroxybenzaldehyde, vanillin, p-coumaric acid, salicylic acid, hesperidin, isoquercitrin, kaempferol-3-glucoside, and luteolin. These compounds are bioactive and contribute to the medicinal properties of the plant. To contextualize these findings, comparisons with other species from the Rutaceae family provide insights into the diversity and consistency of phytochemical profiles across the family.

Several of these compounds are commonly reported in Rutaceae species. For example, hesperidin, the most abundant compound in *Ruta montana* (22.87 mg/g), is also predominant in *Citrus* species, such as *Citrus sinensis* and

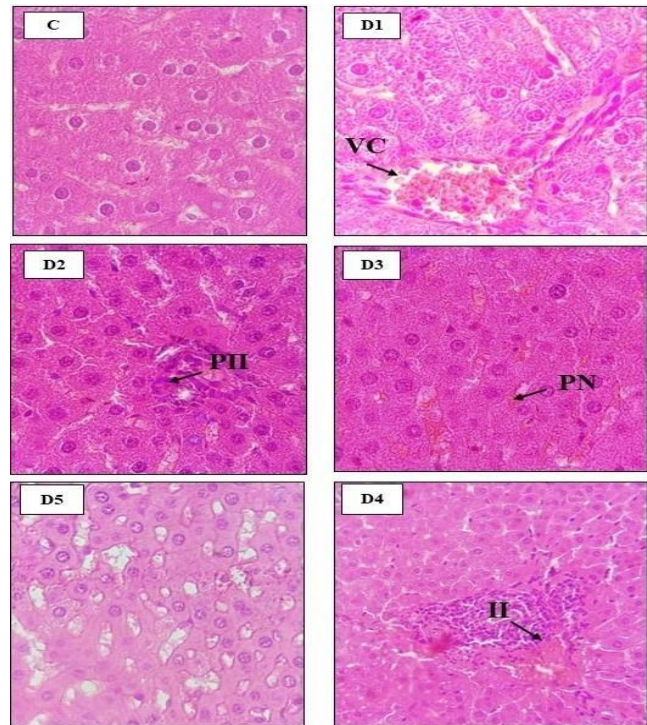
*Citrus aurantium*, where it plays an important role in antioxidant and anti-inflammatory activities. Kawaii *et al.* (1999) highlighted hesperidin's hepatoprotective effects in both *Citrus* and *Ruta* species, further supporting its role in the restoration of liver function in the current study.

Kaempferol-3-glucoside (0.011 mg/g), another compound detected in *Ruta montana*, is also found in *Ruta graveolens*, as reported by Lin et Harnly (2007). Kaempferol derivatives are recognized for their antioxidant and anti-inflammatory properties, and their presence in multiple Rutaceae species highlights their role in mitigating oxidative stress. The low concentration of kaempferol-3-glucoside in *Ruta montana* is consistent with findings from other species, reinforcing its functional importance despite its modest abundance.



**Figure 2.** Mean  $\pm$  SEM of AST: Aspartate aminotransferase (u/l); ALT: Alanine aminotransferase (u/l); ALP: Alkaline phosphatase (u/l); LDH: Lactate dehydrogenase (u/l) TP: Total proteins (g/l); ALB: Albumin (g/l); TB: Total bilirubin (mg/l); GLU: Glucose (g/l) TC: Total cholesterol (g/l); HDL: High-density lipoprotein (g/l); TG: Triglycerides (g/l) of control and rats treated with *Ruta montana* (RM), Tebuconazole (TBC) and combined treatments of Tebuconazole with *Ruta montana* after 50 days of experimental trial. All data are expressed as means  $\pm$ SEM and analyzed by one-way ANOVA test followed by the Tukey test for seven animals in each group (n=7) compared with the control group. values are significantly different (\*p  $\leq$  0.05, \*\*p  $\leq$  0.01, \*\*\*p  $\leq$  0.001) compared with control group.

Luteolin (0.343 mg/g), a flavonoid well-known for its strong antioxidant, anti-inflammatory, and anticancer activities, was detected in *Ruta montana*. Luteolin has also been identified in *Ruta chalepensis* and *Ruta graveolens*, as documented by Raghav *et al.* (2006), demonstrating its widespread occurrence within the Rutaceae family. The presence of luteolin in *Ruta montana* aligns with its documented therapeutic potential in protecting against liver toxicity and inflammation.



**Figure 3.** Microphotograph of liver tissue of (C) the control; (D1) Rats treated with 100 mg/Kg of Tebuconazole; (D2 and D3) Rats treated with 50 mg/Kg and 100 mg/Kg of *Ruta montana* plant; (D4 and D5) Rats treated with mixture of both 100 mg/Kg tebuconazole and 50 mg/Kg and 50 mg/Kg for (D4) and 100 mg/Kg or (D4) of *Ruta montana* plant. Magnification x100. VC : Vascular congestion, PII : Periportal inflammatory infiltrate, PN : Portal necrosis, II : Inflammatory infiltrate. VC : Vascular congestion, PII : Periportal inflammatory infiltrate, PN : Portal necrosis, II : Inflammatory infiltrate.

Similarly, protocatechuic acid, detected at 0.025 mg/g, has been identified in other Rutaceae species, including *Ruta graveolens* and *Citrus* species. El-Sonbaty *et al.* (2019) highlighted protocatechuic acid's hepatoprotective potential, underscoring its role as a potent antioxidant. The inclusion of this compound in *Ruta montana* further supports its use in traditional medicine for liver protection and the mitigation of oxidative damage.

Although salicylic acid (0.205 mg/g) and vanillin (0.044 mg/g) are not as commonly reported in other Rutaceae species, their presence in *Ruta montana* suggests a unique aspect of this species' phytochemical profile. Zaidi *et al.* (2023) emphasized salicylic acid's anti-inflammatory and hepatoprotective properties, adding to the therapeutic potential of *Ruta montana*, complementing the effects of the other phenolic compounds.

To our knowledge, this study presents the first instance where liquid chromatography-tandem mass spectrometry (LC-MS/MS) has been employed to analyze the ethanolic extract of *Ruta montana*. The LC-MS findings correspond closely with research by Szopa *et al.* (2012), who demonstrated the potential of the Rutaceae family to yield protocatechuic acid and p-coumaric acid. Our results also align with the work of Asgharian *et al.* (2020), who identified luteolin in *Ruta graveolens*, and Al-Jaberi *et al.* (2023), who confirmed the presence of hesperidin in *Ruta chalepensis*.

Interestingly, our analysis did not detect certain phenolic compounds that have been reported in previous studies on *Ruta montana*. Bouhenna *et al.* (2023) noted the presence of compounds such as rutamontine, umbelliferone, daphnoretin, daphnoretin methyl ether, scopoletin, chalepin, rutaretin, 6,7,8-trimethoxycoumarin, 4-O-feruloyl quinic acid, 4-O-p-coumaroylquinic acid, cnidoside A, suberenone, dimethylallyl-herniarine, 6,8-C-dihexosyl-apigenin, isorhamnetin-3-O-rutinoside, and sinapoylferuloylxlosapoyhex in their analysis of crude, n-butanol, chloroform, and ethyl acetate extracts from the aerial parts of *Ruta montana*.

This discrepancy between our findings and previous reports could be attributed to several factors. Bouzana *et al.* (2023) suggested that variations in the phytochemical composition might arise due to differences in plant species studied, the quantity and types of standards used, or the geographical location of the plant collection. Additionally, extraction methods play a critical role in determining the phenolic profile of plants. Bouhenna *et al.* (2023) pointed out that solvents such as n-butanol and ethyl acetate might extract a broader range of compounds than ethanol. Other factors, such as the developmental stage of the plant, harvesting season, plant part used, and storage conditions, as well as the analytical method employed, may also contribute to differences in chemical composition (Benkhaira *et al.* 2022; Jaisamut *et al.* 2021).

Finally, the bioactive compounds identified in *Ruta montana*, particularly hesperidin, luteolin, and kaempferol-3-glucoside, likely play a significant role in the observed hepatoprotective effects. The variability in phytochemical composition underscores the need for further studies to explore the influence of different environmental and methodological factors on the bioactive profile of *Ruta montana* and other Rutaceae species.

Exposure to Tebuconazole reduced adipose tissue accumulation, aligning with findings by Berrouague *et al.* (2019). This outcome may stem from diminished food intake, muscle weakness, or potential toxicity (Lafi *et al.* 2017, Ben Othmène *et al.* 2020). Furthermore, heightened water consumption was observed, potentially indicating a physiological response to mitigate the fungicide's toxicity (Chaâbane *et al.* 2017). Alterations in body mass often serve as predictive indicators of adverse reactions to pharmacological and chemical exposures as toxicity assessments typically encompass monitoring changes in body and organ mass (Dahamna *et al.* 2011, Hilaly *et al.* 2004). This investigation shows that Tebuconazole impacts rat body mass following sub-chronic oral administration. In the context of a sub-chronic study, a marginal fluctuation in body mass was noted among rats administered oral doses of *Ruta montana* extract (RM 50 RM 100) and those exposed to a combined regimen of Tebuconazole and *Ruta montana* over a 50-day continuum. These findings are according to Merghem *et al.* (2013).

Regarding the hepatic relative and the absolute weights, no notable differences were observed in the weights of the Tebuconazole-exposed group and the other treatment groups compared to the control hepatic relative and absolute weights. However, a notable decrease in the absolute liver weight was observed in combination-treated groups. The hepatic reduction may result from alterations in hepatorenal blood flow (Rous, 1920 ; Rubin *et al.* 1965).

Biochemical assays serve as primary indicators of organ-specific damage (Awe *et al.* 2013). Enzymes such as Alanine transaminase (ALT) and Aspartate transaminase (AST) are widely acknowledged as biomarkers of liver function and potential toxicity (Rahman *et al.* 2011; Mdhului 2003). An elevation in AST and ALT serum levels typically reflects damage to hepatic parenchymal cells, as detailed by Slimani *et al.* (2021) and Silini *et al.* (2022). Our findings reveal elevated levels of plasma biochemical markers such as ALT, AST, LDH, and ALP in rats treated with TBC. These observations are consistent with the study by Berrouague *et al.* (2019), which reported increased levels of ALT and AST in TBC-treated rats, indicating liver dysfunction. Similar results were reported by Ku *et al.* (2021); mice exposed to Tebuconazole showed a significant rise in serum AST and ALT levels, suggesting liver tissue impairment. The enzymatic activity increases may be due to compromised cellular membrane integrity within hepatic tissues, leading to enhanced necrosis, hepatocyte degradation, and increased plasma aminotransferase activities (Arfat *et al.* 2014; Slimani *et al.* 2014). Disturbances in hepatic enzymes, particularly within the cytochrome P450 family, notably Cyp1, play a significant role in the metabolism of exogenous substances, indicating the liver's pivotal role in detoxification processes (Guengerich, 2017). The induction of TBC-related toxicity likely initiates lipid membrane peroxidation, demonstrating the rapid impact of peroxides on the structural and functional dynamics of cellular membranes, including endoplasmic reticulum, lysosomes, and mitochondria (Toughan *et al.* 2018). Furthermore, empirical data suggest that damaged or inflamed hepatic cells may release a broader spectrum of metabolites and compounds, including liver enzymes, into the bloodstream, implying that elevated enzyme levels in plasma may reflect the extent of hepatocyte damage and necrosis (Ramaiah 2007; Bouzekri *et al.* 2021).

Moreover, the Administration of TBC significantly elevated overall cholesterol levels, potentially attributed to pesticide-induced alterations in hepatic cell membrane permeability (Berrouague *et al.* 2019). This rise could signify potential obstructions in the hepatic bile duct, impeding cholesterol release into the duodenum (Berrouague *et al.* 2019), implying the presence of lipid metabolic disorders and liver damage (Chaâbane *et al.* 2017; Ben Othmène *et al.* 2020). Reduced albumin levels in TEB-treated rats indicate compromised liver cell function and diminished hepatic protein synthesis capacity (Zhang *et al.* 2017). Furthermore, heightened total bilirubin levels may suggest liver damage, impacting hepatocytes involved in glucuronidation and erythrocyte hemolysis (Erlinger, 2014; Mulyati *et al.* 2020).

Herbal treatments are frequently used to prevent and treat liver diseases due to their ability to resist oxidative damage caused by xenobiotics, as explained by Hussein *et al.* (2016). *Ruta montana*, an evergreen shrub belonging to the Rutaceae family, has been documented for its pharmacological properties, as outlined in the studies by Ozenda. (2000), Da Silva *et al.* (2006), and Pelletier. (1983). Administration of *Ruta montana* to male rats shows a notable decrease in aspartate aminotransferase (AST) and an increase in phosphatase alkaline. Merghem *et al.* (2013) reported no significant changes in the activities of Alanine transaminase (ALT) and Aspartate transaminase (AST) nor albumin concentrations, indicating that prolonged administration of *Ruta montana* extract does not adversely affect hepatocyte function or disrupt metabolic activities. However, research by Mahdeb *et al.* (2023) identified minor elevations in ASAT and ALAT levels, with a marked increase in PAL levels. The rise in alkaline phosphatase implies a simple alteration in liver functionality, as the enzyme's activity serves as a potential diagnostic indicator for hepatic damage in humans (Limdi et Hyde, 2003). This phenomenon could potentially arise from the organism's adaptive mechanisms triggered in response to prolonged exposure to elevated concentrations over an extended duration (Fernandes *et al.* 2011). Conversely, Merghem *et al.* (2013) proposed that the antioxidant actions attributed to polyphenols within the *Ruta montana* extract might have contributed to maintaining normal plasma liver enzyme levels.

The concurrent administration resulted in the restoration of most biochemical parameters (Bouzekri *et al.* (2023). The revitalization of biochemical attributes is intimately linked to nine molecular compounds within *Ruta montana*, notably Hesperidin (C<sub>28</sub>H<sub>34</sub>O<sub>15</sub>), a flavonoid abundant in citrus fruits (Ali *et al.* 2023). Hesperidin exerts its effects by inhibiting inducible nitric oxide synthase (iNOS), thereby reducing hepatic nitric oxide (NO) levels and lipid peroxidation (Xiaoting *et al.* 2011; , Tabeshpour *et al.* 2020). It enhances antioxidant defenses by augmenting total antioxidant capacity (TAC) and glutathione (GSH) levels, concomitantly decreasing protein carbonyl (PC) levels to shield proteins from damage (Nasehi *et al.* 2023). Furthermore, Hesperidin reinstates the activities of antioxidant enzymes such as superoxide dismutase (SOD) and catalase while also modulating the expressions of genes associated with fibrosis and inflammation (Ali *et al.* 2023). Isoquercitrin (IQ) manifests notable protective attributes against oxidative stress through the modulation of critical factors such as NADPH oxidase 4 (Nox4) and dual oxidase 1 (Duox1), concurrently augmenting the expression of nuclear factor erythroid 2-related factor 2 (Nrf2) and superoxide dismutase 2 (SOD2) (Qiu *et al.* 2019 ; Qin *et al.* 2018). Luteolin (LUT) showcases pronounced antioxidant properties coupled with immunomodulatory effects, influencing biomarkers and inflammatory cytokines (Zhang *et al.* 2016). Salicylic acid (SA) demonstrates hepatoprotective prowess, evident in its capacity to mitigate liver damage markers while reinstating enzymatic activities (Zaidi *et al.* 2023). P-coumaric acid (PCA) underscores its antioxidant potential alongside a

spectrum of beneficial effects encompassing anti-inflammatory and neuroprotective properties (Guvén *et al.* 2015 ; Parvizi *et al.* 2020). Vanillin showcases hepatoprotective capabilities by attenuating liver enzyme levels and enhancing antioxidant enzyme activity (Banerjee *et al.* 2018 ; Tiwari *et al.* 2020). Protocatechuic acid (PC) emerges as a potent antioxidant agent while modulating cellular pathways implicated in oxidative stress-induced apoptosis (El-Sonbaty *et al.* 2019; Liu *et al.* 2023). Finally, Kaempferol-3-glucoside (K-3-G) exhibits robust antioxidant activity and plays a pivotal role in replenishing glutathione levels, thereby maintaining cellular redox balance (Wang *et al.* 2015). These findings collectively underscore the therapeutic potential of these bioactive compounds across various physiological contexts, particularly in addressing liver damage and related ailments.

## 5. Conclusion

These experiments shed light on the changes that tebuconazole intoxication induces in biochemical values and hepatic tissues. The treatments indicate that natural substances of the *Ruta* species, especially *Ruta montana*, exhibit promising reservoirs of naturally occurring compounds possessing significant biological activity. *Ruta* extracts and isolated chemicals have demonstrated a wide range of potential applications to improve markers of hepatic injury by normalizing most of the blood parameters, thereby contributing to the enhancement of the value of these plants. This suggests that more investigation is necessary to explore the therapeutic approaches that target liver function abnormalities.

## Declarations

The authors report no conflicts of interest related to this study.

## Acknowledgement

This research received funding from the Algerian Ministry of Higher Education and Scientific Research.

## References

- Adamska-Szewczyk A., Glowinski K., Baj T. (2016). Furocholine alkaloids in plants from Rutaceae family: A review, *Current Issues in Pharmacy and Medical Sciences*, **29**(1):33–38. doi:10.1515/cipms-2016-0008.
- Akinrinde A.S., Afolayan A.J., Bradley G. (2018). *Phytochemical Composition and Antioxidant Activities of Dianthus Thunbergii Hooper and Hypoxis Argentea Harv Ex Baker: Plants Used for the Management of Diabetes Mellitus in Eastern Cape*, South Africa, *Pharmacognosy Magazine*, **14**(54):195–202. doi:10.4103/pm.pm\_157\_17.
- Al-Jaberi A.M.Z., Al-Fadal S.A.M., Abdul-Jalil T.Z. and Al-Wafi H. (2023). HPLC Isolation of Rutin, Hesperidin and Quercetin from *Ruta Chalepensis* Extract Growing in Iraq, *Pharmacognosy Journal*, **15**(4):606–611. <https://doi.org/10.5530/pj.2023.15.127>.
- Ali Y.A., Soliman H.A., Abdel-Gabbar M., Ahmed N.A., Attia K.A.A., Shalaby F.M., *et al.* (2023). Rutin and Hesperidin Revoke the Hepatotoxicity Induced by Paclitaxel in Male Wistar Rats via Their Antioxidant, Anti-inflammatory, and Antiapoptotic Activities, *Evidence-Based Complementary and*

- Alternative Medicine*, 2023:2738351.  
<https://doi.org/10.1155/2023/2738351>.
- Allouni, R., Guergour, H., Mahdeb, N., Omrane, V. and Bouzidi, A. (2017). Acute toxicity study of the total alkaloids of *Ruta montana* in male mice, *International Journal of Pharmacognosy and Phytochemical Research*, **9**(8), 1060–1066. <https://doi.org/10.25258/phyto.v9i08.9612>.
- Alter M.J. (2006). Epidemiology of viral hepatitis and HIV coinfection, *Journal of Hepatology*, **44**(1):S6–S9. doi: 10.1016/j.jhep.2005.11.004.
- Arfat Y., Mahmood N., Tahir M.U., Rashid M., Anjum S., Zhao F., *et al.* (2014). Effect of Imidacloprid on hepatotoxicity and nephrotoxicity in male albino mice, *Toxicology Reports*, **1**:554–561.
- Asao T. and Asaduzzaman M. (2018). *Phytochemicals: Source of Antioxidants and Role in Disease Prevention*, BoD – Books on Demand.
- Asgharian S., Hojjati M.R., Ahrari M., Bijad E., Deris F., Lorigooini Z. (2020). *Ruta graveolens* and rutin, as its major compound, investigating their effect on spatial memory and passive avoidance memory in rats, *Pharmaceutical Biology*, **58**(1):447–453.  
<https://doi.org/10.1080/13880209.2020.1762669>.
- Awe E.O., Banjoko S.O. (2013). Biochemical and haematological assessment of toxic effects of the leaf ethanol extract of *Petroselinum crispum* (Mill) Nyman ex A.W. Hill (Parsley) in rats, *BMC Complementary Medicine*, **13**(75):1–6. <http://www.biomedcentral.com/1472-6882/13/75>.
- Banerjee G., Chattopadhyay P. (2018). Vanillin Biotechnology, the perspectives and future, *Journal of the Science of Food and Agriculture*, **99**(2):499–506.  
<https://doi.org/10.1002/jsfa.9303>.
- Ben Othmène Y., Monceaux K., Karoui A., Ben Salem I., Belhadeff A., Abid-Essefi S. *et al.* (2020). Tebuconazole induces ROS-dependent cardiac cell toxicity by activating DNA damage and mitochondrial apoptotic pathway, *Ecotoxicology and Environmental Safety*, **204**:111040. doi:10.1016/j.ecoenv.2020.111040.
- Ben-Saad H., Feki A., Boudawara O., Hakim A., Ben Amara I. (2017). Effects of selenium on tebuconazole-induced hepatotoxicity in adult rats, *Journal of Pharmacognosy*, **6**(6):105–109.
- Benkhaira N., Ibnouda Koraichi S., Fikri-Benbrahim K. (2022). *Ruta Montana* (L.) L., an insight into its medicinal value, phytochemistry, biological properties, and toxicity, *Journal of Herbmed Pharmacology*, **11**(3):305–319.  
<https://doi.org/10.34172/jhp.2022.36>.
- Berrouague S., Rouag M., Khaldi T., Boumendjel A., Boumendjel M., Taibi F., *et al.* (2019). Efficacy of *Allium sativum* oil to alleviate tebuconazol-induced oxidative stress in the liver of adult rats, *Cellular and Molecular Biology*, **65**(8):23–31. <http://dx.doi.org/10.14715/cmb/2019.65.8.5>.
- Bošković N., Bílková Z.K., Šudoma M., Bielská L., Škulcová L., Ribitsch D., *et al.* (2021). Conazole fungicides epoxiconazole and tebuconazole in biochar amended soils: Degradation and bioaccumulation in earthworms, *Chemosphere*, **274**:129700. doi:10.1016/j.chemosphere.2021.129700.
- Bouhenna M.M., Bendif H., Segueni N., Khalfa H., Djadoudi A., Tahraoui S., *et al.* (2023). Phytochemical Profiling, LC-MS Analyses, Cytotoxicity, Antioxidant, and Antimicrobial Activities of *Ruta Montana*, an Ethnomedicinally Important Plant in Algeria, *Current Bioactive Compounds*, **20**(4):1–10. <https://doi.org/10.2174/1573407219666230606140634>.
- Bouzana A., Chekroud Z., Becheker I., Sakhraoui N., Bouzenad N., Bensouici C. (2023). Phytochemical Analysis by LC-MS/MS and in Vitro Antioxidant Activity of the Algerian Endemic Plant *Dianthus Sylvestris Subsp. Aristidis* (Batt.) Greuter & Burdet, *Global Nest Journal*, **25**(7):113–119. <https://doi.org/10.30955/gnj.005047>.
- Bouzekri A., Slimani S., Nassar M., Abdenmour C., Heddami S. (2023). *Tribulus terrestris* methanolic extract modulates Spirotetramat-induced liver and kidney toxicity in domestic pigeons (*Columba livia domestica*). *Journal of Animal and Plant Sciences*, **33**(4):958–970. <https://doi.org/10.36899/japs.2023.4.0689>.
- Brown P.N., Murch S.J., Shipley P. (2012). Phytochemical diversity of cranberry (*Vaccinium macrocarpon* Aiton) cultivars by anthocyanin determination and metabolomic profiling with chemometric analysis, *Journal of Agricultural and Food Chemistry*, **60**(1):261–271. doi: 10.1021/jf2033335.
- Cepa S., Potter D., Wong L., Schutt L., Tarrant J., Pang J., *et al.* (2018). Individual serum bile acid profiling in rats aids in human risk assessment of drug-induced liver injury due to BSEP inhibition, *Toxicology and Applied Pharmacology*, **338**:204–213. <https://doi.org/10.1016/j.taap.2017.11.007>.
- Chaâbane M., Koubaa M., Soudani N., Elwej A., Grati M., Jamoussi K., *et al.* (2017). Nitraria retusa fruit prevents penconazole-induced kidney injury in adult rats through modulation of oxidative stress and histopathological changes, *Pharmaceutical Biology*, **55**:1061–1073.
- Dahamna S., Belguet A., Bouamra D., Guendouz A., Mergham M., Harzallah D. (2011). Evaluation of the toxicity of cypermethrin pesticide on organs weight loss and some biochemical and histological parameters, *Communications in Agricultural and Applied Biological Sciences*, **76**(4):915–921.
- De Giffoni de Carvalho J.T., Da Silva Baldivia D., Leite D.F., De Araújo L.C.A., De Toledo Espindola P.P., Antunes K.A., *et al.* (2019). Medicinal Plants from Brazilian Cerrado: Antioxidant and Anticancer Potential and Protection against Chemotherapy Toxicity, *Oxidative Medicine and Cellular Longevity*, 2019(4):1–16. doi:10.1155/2019/3685264.
- De Rossi C., Bieri R., Riefstahl J. (2003). Organic pollutants in precipitation: Monitoring of pesticides and polycyclic aromatic hydrocarbons in the region of Trier (Germany), *Physics and Chemistry of the Earth, Parts A/B/C*, **28**(8):307–314. doi:10.1016/S1474-7065(03)00052-4.
- Djeridane A., Yousfi M., Nadjemi B., Boutassouna D., Stocker P., Vidal N. (2006). Antioxidant activity of some Algerian medicinal plants extracts containing phenolic compounds, *Food Chemistry*, **97**(4):654–660. doi:10.1016/j.foodchem.2005.04.028.
- Dolatkahi M., Dolatkahi A., Nejad J.B. (2014). Ethnobotanical study of medicinal plants used in Arjan-Parishan protected area in Fars Province of Iran, *Avicenna Journal of Phytomedicine*, **4**(6):402–412.
- El-Ouady F., Eddouks M. (2021). *Ruta montana* evokes antihypertensive activity through an increase of prostaglandins release in L-NAME-induced hypertensive rats, *Endocrine, Metabolic & Immune Disorders - Drug Targets*, **21**(2):305-314.
- El-Sonbaty Y.A., Suddek G.M., Megahed N., Gameil N.M. (2019). Protocatechuic acid exhibits hepatoprotective,



- vasculoprotective, antioxidant and insulin-like effects in dexamethasone-induced insulin-resistant rats, *Biochimie*, **167**:119-134. doi:10.1016/j.biochi.2019.09.011.
- Erlinger S., Arias I.M., Dhumeaux D. (2014). *Gastroenterology*, **146**:1625–1638.
- Erenler R., Yaman C., Demirtas I., Alma M.H. (2023). Phytochemical Investigation of *Hypericum heterophyllum* Flowers: LC-ESI-MS/MS Analysis, Total Phenolic and Flavonoid Contents, Antioxidant Activity, *Natural Products Journal*, **13**(7):1–9. <https://doi.org/10.2174/2210315513666230112165545>.
- Farid O., Hebi M., Ajebli M., EL Hidani A., Eddouks M. (2017). Antidiabetic effect of *Ruta montana* L. in streptozotocin-induced diabetic rats, *Journal of Basic and Clinical Physiology and Pharmacology*, **28**(3):275–282. doi:10.1515/jbcpp-2016-0030.
- Fernandes M.D., Iano F.G., Rocia V., Yanai M.M., Leite A.D., Furlani T.A., et al. (2011). Alkaline Phosphatase Activity in Plasma and Liver of Rats Submitted to Chronic Exposure to Fluoride, *Brazilian Archives of Biology and Technology*, **54**(6):1187–1192. <https://doi.org/10.1590/s1516-89132011000600014>.
- Ghedjati N., Mahdeb N., Bouzidi A. (2022). Acute and Subchronic Toxicity Study of Methanol Extract of the Aerial Parts of *Ruta montana* L. on Adult Female Wistar Rats, *Tropical Journal of Natural Product Research*, **6**(8):1203–1209. doi:10.26538/tjnpr/v1i4.5.
- Goetz A.K., Ren H., Schmid J.E., Blystone C.R., Thillainadarajah I., Best D.S., et al. (2007). Disruption of testosterone homeostasis as a mode of action for the reproductive toxicity of triazole fungicides in the male rat, *Toxicological Sciences*, **95**(1):227–239. doi:10.1093/toxsci/kfl124.
- Guengerich F.P. (2017). Intersection of the roles of cytochrome P450 enzymes with xenobiotic and endogenous substrates: relevance to toxicity and drug interactions, *Chemical Research in Toxicology*, **30**(1):2–12. doi: 10.1021/acs.chemrestox.6b00226.
- Guvan M., Aras A.B., Akman T., Sen H.M., Ozkan A., Salis O., et al. (2015). Neuroprotective effect of p-coumaric acid in rat model of embolic cerebral ischemia, *Iranian Journal of Basic Medical Sciences*, **18**(4):356–363.
- Hilaly J.E., Israïli Z.H., Lyoussi B. (2004). Acute and chronic toxicological studies of *Ajuga reptans* in experimental animals, *Journal of Ethnopharmacology*, **91**(1):43–50. doi:10.1016/j.jep.2003.11.009.
- Hussein J., Abo El-Matty D., El-Khayat Z., Abdel Latif Y., Saleh S., Farrag A.R., Abd-ElGhany W. (2016). Kiwifruit extract attenuates DNA damage and vitamins reduction in indomethacin-induced experimental gastric ulcer, *Jokull Journal*, **65**(12):2–16.
- Jaisamut P., Wanna S., Thanakoon A., Saejew S., Saowapark N., Suchato W., et al. (2021). Evaluation of Microwave-Assisted Extraction Method for Preparation and Assessment of Thai Herbal Medicine Oral Tablets With Enriched Phytochemical Compounds, *AAPS PharmSciTech*, **22**.
- Joshi S.C., Gulati N., Sharma B., Sharma P. (2016). Effects of tebuconazole (a fungicide) on reproduction of male rats, *International Journal Of Pharma Research and Health Sciences*, **4**:1489–1494.
- Kara Ali W., Ihoual S., Abidli N. (2016). Antioxidant and MDR reversal activity in resistant human ovarian cancer cells of methanolic extract from *Ruta montana* located in the North of Algeria, *Der Pharma Chemica*, **8**(12):215–223. <http://derpharmachemica.com/archive.html>.
- Kalt W., Ryan D.A., Duy J.C., Prior R.L., Ehlenfeldt M.K., Vander Kloet S.P. (2001). Interspecific variation in anthocyanins, phenolics, and antioxidant capacity among genotypes of highbush and lowbush blueberries (*Vaccinium section Cyanococcus* spp.), *Journal of Agricultural and Food Chemistry*, **49**(10):4761–4767. doi: 10.1021/jf010653e.
- Kawaii, S., Tomono, Y., Katase, E., Ogawa, K., & Yano, M. (1999). Antiproliferative activity of flavonoids on several cancer cell lines. *Bioscience, Biotechnology, and Biochemistry*, **63**(5): 896–899.
- Ku T., Zhou M., Hou Y., Xie Y., Li G., Sang N. (2021). Tebuconazole induces liver injury coupled with ROS-mediated hepatic metabolism disorder, *Ecotoxicology and Environmental Safety*, **220**:112309. doi:10.1016/j.ecoenv.2021.112309.
- Kumar, S., Pandey, A.K. (2013). Chemistry and biological activities of flavonoids: An overview. *The Scientific World Journal*, **2013**: 162750.
- Lafi B., Chaâbane M., Elwej A., Grati M., Jamoussi K., Mnif H., et al. (2017). Effects of co-exposure to imidacloprid and gibberellic acid on redox status, kidney variables and histopathology in adult rats, *Archives of Physiology and Biochemistry*, **124**(2):1–10. doi:10.1080/13813455.2017.1371195.
- Li Y., Dong F., Liu X., Xu J., Li J., Kong Z., et al. (2012). Simultaneous enantioselective determination of triazole fungicides in soil and water by chiral liquid chromatography/tandem mass spectrometry, *Journal of Chromatography A*, **1224**:51-60. doi:10.1016/j.chroma.2011.12.044.
- Limdi J.K., Hyde G.M. (2003). Evaluation of abnormal liver function tests, *Postgraduate Medical Journal*, **79**(932):307–312. doi:10.1136/pmj.79.932.307.
- Lin, L.Z. and Harnly, J.M. (2007). Identification of the phenolic components of Rutaceae species by HPLC-MS. *Journal of Agricultural and Food Chemistry*, **55**(8): 2873-2884.
- Liu C., Zhang C., Li M., Fu J.L., Yang H., Ge W., Shi Y., Lü Y., Huang C. (2023). High Affinity of Protocatechuic Acid to Human Serum Albumin and Modulatory Effects against Oxidative Stress and Inflammation in Alveolar Epithelial Cells: Modulation of Pulmonary Fibrosis, *Arabian Journal of Chemistry*, **16**(11):105225. <https://doi.org/10.1016/j.arabjc.2023.105225>.
- Mahdeb, N., Attafi, K., Bouhouhou, S., Rima, A., & Abdelouhab, B. (2023). Acute and Subacute Toxicity of *Ruta Montana* Extract to Female Rats: Effect on Liver, Kidneys and Ovaries. *Turkish Journal of Agriculture - Food Science and Technology*, **11**(10), 1862–1870. <https://doi.org/10.24925/turjaf.v11i10.1862-1870.5768>
- Martoja R. (1967). *Initiation aux Techniques de l’Histologie Animale*, Masson, Paris, p. 345.
- Mdhluhi M. (2003). Toxicological and antifertility investigations of oleanolic acid in male vervet monkeys (*Chlorocebus aethiops*), PhD Thesis, Discipline of Physiological Sciences, University of the Western Cape, Cape Town, South Africa.
- Merghem M., Dahamna S., Rezzagui A., Boussahel S., Belguet A., Dehimi K., Harzallah D. (2013). Acute and Chronic Toxicity of Aqueous Extract of *Ruta Montana* L. in Rodents, *Pharmacogn Commun*, **3**(2):50-57. <https://doi.org/10.5530/pc.2013.2.11>.
- Mohammedi H., Mecherara-Idjeri S., Hassani A. (2020). Variability in essential oil composition, antioxidant and antimicrobial activities of *Ruta montana* L. collected from different geographical regions in Algeria, *J Essential Oil Res*, **32**(1):88-101. <https://doi.org/10.1080/10412905.2019.1660238>.

- Mulyati, Mardhatillah T.D., Widiyanto S. (2020). Liver function of hypertriglyceridemia (HTG) Wistar rats (*Rattus norvegicus* Berkenhout, 1769) with treatments of \**Arthrospira maxima*\* Setchell et Gardner and \**Chlorella vulgaris*\* Beijerinck, AIP Conf Proc, 2260(1):040013. <https://doi.org/10.1063/5.001619>.
- Nasehi Z., Kheiripour N., Akhavan Taheri M., Ardjmand A., Jozi F., Shahaboddin M.E. (2023). Efficiency of Hesperidin against Liver Fibrosis Induced by Bile Duct Ligation in Rats, *BioMed Research International*, 2023:5444301. <https://doi.org/10.1155/2023/5444301>.
- Ozenda P. (2007). Les Végétaux, organisation et diversité biologique, 2nd Edition, Dunod, Paris, p. 528.
- Parvizi F., Yaghmaei P., Haeri Rohani S.A., Mard S.A. (2020). Hepatoprotective Properties of P-Coumaric Acid in a Rat Model of Ischemia-Reperfusion, *Avicenna Journal of Phytomedicine*, 10(6):633–640.
- Pelletier S.W. (1983). Alkaloids, Chemical and Biological Perspectives, Pergamon, London. ISBN: 9780080527000.
- Perez-Rodriguez V., Souders C.L., Tischuk C., Martyniuk C.J. (2019). Tebuconazole reduces basal oxidative respiration and promotes anxiolytic responses and hypoactivity in early-staged zebrafish (*Danio rerio*), *Comparative Biochemistry and Physiology Part C*, 217:87-97. doi:10.1016/j.cbpc.2018.11.01.
- Qiu J., Yang X., Wang L., Zhang Q., Ma W., Huang Z., et al. (2019). Isoquercitrin promotes peripheral nerve regeneration through inhibiting oxidative stress following sciatic crush injury in mice, *Ann Transl Med*, 7:680.
- Qin G., Ma J., Huang Q., Yin H., Han J., Li M., et al. (2018). Isoquercetin Improves Hepatic Lipid Accumulation by Activating AMPK Pathway and Suppressing TGF- $\beta$  Signaling on an HFD-Induced Nonalcoholic Fatty Liver Disease Rat Model, *International Journal of Molecular Sciences*, 19(12):4126. <https://doi.org/10.3390/ijms19124126>.
- Raghav, S.K., Gupta, B., Agrawal, C., Goswami, K., & Das, H.R. (2006). Antioxidant activity of luteolin against acrolein-induced lung injury. *Toxicology*, 220(2-3): 67-72.
- Rahman M.F., Siddiqui M.K., Jamil K. (2001). Effects of Vepacide (*Azadirachta indica*) on aspartate and alanine aminotransferase profiles in a subchronic study with rats, *Human & Experimental Toxicology*, 20(5):243–249. doi:10.1191/096032701678227730.
- Ramaiah S.K. (2007). A toxicologist guide to the diagnostic interpretation of hepatic biochemical parameters, *Food and Chemical Toxicology*, 45(9):1551–1557. <https://doi.org/10.1016/j.fct.2007.06.007>.
- Rous P., Larimore L.D. (1920). Relation of the portal blood to liver maintenance: a demonstration of liver atrophy conditional on compensation, *Journal of Experimental Medicine*, 31(5):609–632. doi:10.1084/jem.31.5.609.
- Rubin E., Gevartz N.R., Cohan P., Tomita F. and Jacobson J.H. (1965). Liver Cell Damage Produced by Portacaval Shunts, *Experimental Biology and Medicine*, 118(1):235–237. doi:10.3181/00379727-118-29807.
- Slimani S., Boulakoud M.S., Abdennour C. and Gueddah D. (2014). Antracol administration has disturbed the reproductive cycle of domestic pigeon *Columba livia domestica*, *Advances in Environmental Biology*, 8(24):82–91.
- Silini S., Slimani S., Abdennour C. (2022). Hepatotoxicity induced by chronic exposure to deltamethrin, abamectin and their mixture in male pigeon (*Columba livia domestica*), *Uttar Pradesh Journal of Zoology*, 43(20):62–69. doi: <https://doi.org/10.56557/upjz/2022/v43i203199>.
- Slimani S., Silini S., Abdennour C. (2021). The fungicide thiram induced hepatic and renal injuries in domestic pigeons (*Columba livia domestica*), *Annals of Clinical and Analytical Medicine*, 12(5):547–552. doi: <https://doi.org/10.4328/acam.20620>.
- Szopa A., Ekiert H., Szweczyk A., Fugas E. (2012). Production of bioactive phenolic acids and furanocoumarins in in vitro cultures of *Ruta graveolens* L. and *Ruta graveolens* ssp. *divaricata* (Tenore) Gams under different light conditions, *Plant Cell Tissue Organ Cult*, 110(3):329–336. <https://doi.org/10.1007/s11240-012-0154-5>.
- Tabeshpour J., Hosseinzadeh H., Hashemzaei M., Karimi G. (2020). A review of the hepatoprotective effects of hesperidin, a flavanon glycoside in citrus fruits, against natural and chemical toxicities, *Daru*, 28(1):305–317. doi: 10.1007/s40199-020-00344-x.
- Tamura K., Inoue K., Takahashi M., Matsuo S., Irie K., Kodama Y., et al. (2013). Dose-response involvement of constitutive androstane receptor in mouse liver hypertrophy induced by triazole fungicides, *Toxicology Letters*, 221(1):47–56. doi:10.1016/j.toxlet.2013.05.011.
- Tiwari R., Chourasia A., Chaturvedi A., Ganeshpurkar A., Dubey N. (2020). Evaluation of Hepatoprotective Effect of Vanillin in Isoniazid-Rifampicin Induced Hepatocellular Damage, *Free Radicals Antioxidants*, 10(1):432–446. <https://doi.org/10.5530/fra.2020.1.8>.
- Toughan H., Khalil S.R., El-Ghoneimy A., Awad A., Seddek A.S.H. (2018). Effect of dietary supplementation with *Spirulina platensis* on Atrazine-induced oxidative stress-mediated hepatic damage and inflammation in the common carp (*Cyprinus carpio* L.), *Ecotoxicology and Environmental Safety*, 149:135–142. <https://doi.org/10.1016/j.ecoenv.2017.11.018>.
- Wang Y., Tang C., Zhang H. (2015). Hepatoprotective Effects of Kaempferol 3-O-Rutinoside and Kaempferol 3-O-Glucoside from *Carthamus tinctorius* L. on CCl<sub>4</sub>-Induced Oxidative Liver Injury in Mice, *Journal of Food and Drug Analysis*, 23(2):310–317. <https://doi.org/10.1016/j.jfda.2014.10.005>.
- Xiaoting L., Xiangyun Z., Shumei L., Minghua D., Liang X. (2010). Effect of hesperidin on expression of inducible nitric oxide synthase in cultured rabbit retinal pigment epithelial cells, *Advances in Experimental Medicine and Biology*, 664:193–201. [https://doi.org/10.1007/978-1-4419-1399-9\\_22](https://doi.org/10.1007/978-1-4419-1399-9_22).
- Yang J.D., Liu S.H., Liao M.H., Chen R.M., Liu P.Y., Ueng T.H. (2019). Effects of tebuconazole on cytochrome P450 enzymes, oxidative stress, and endocrine disruption in male rats, *Environmental Toxicology*, 33(8):899–907. doi:10.1002/tox.22575.
- Zhang J., Song W., Sun Y., Shan A. (2017). Effects of phoxim-induced hepatotoxicity on SD rats and the protection of vitamin E, *Environmental Science and Pollution Research*, 24(32):24916–24927. doi:10.1007/s11356-017-0104-1.
- Zhang Q., Yang J., Wang J. (2016). Modulatory Effect of Luteolin on Redox Homeostasis and Inflammatory Cytokines in a Mouse Model of Liver Cancer, *Oncology Letters*, 12(6):4767–4772. <https://doi.org/10.3892/ol.2016.5291>.
- Zeichen de Sa R., Rey A., Arganaraz E., Bindstein E. (2000). Perinatal toxicology of *Ruta chalepensis* (Rutaceae) in mice,

*Journal of Ethnopharmacology*, **69**(2):93–98.  
doi:10.1016/S0378-8741(98)00232-3.

Zaidi S.N.F., Usman G., Usman S.M. (2023). Salicylic Acid Protects Gentamicin-induced Hepatotoxicity, study in Rabbits, *Pakistan Journal of Pharmaceutical Sciences*, **36**(3):873–878.  
<https://doi.org/10.36721/PJPS.2023.36.3.REG.873-878.1>.